



Surgical management of obstructive sleep apnea

Kasey K. Li, MD, DDS*

Stanford University Sleep Disorders and Research Center, 401 Quarry Road, Stanford, CA 94305, USA

Despite the effectiveness of nasal continuous positive airway pressure (CPAP) in the management of obstructive sleep apnea (OSA), patient acceptance and tolerance remain a significant problem. Consequently, surgery remains a highly desirable option for many patients and should be considered. Several major surgical advances have improved significantly the understanding and treatment of OSA since the first tracheotomy performed by Kuhlo [1] for the treatment of upper airway obstruction in “Pickwickian” subject. Uvulopalatopharyngoplasty (UPPP) was initially described by Ikematsu [2] and later popularized by Fujita [3]. UPPP improves oropharyngeal obstruction and is the most commonly performed procedure for the treatment of OSA. With the increased recognition of hypopharyngeal airway obstruction as a major contributing factor of OSA, genioglossus and hyoid advancement were later developed [4,5] to improve surgical treatment outcomes. In the early 1980s, numerous investigators reported that surgical advancement of the mandible can improve OSA [6–8]. To maximize the extent of mandibular advancement, concurrent maxillary advancement was subsequently advocated [9]. Maxillomandibular advancement also has been noted to widen the retropalatal airway, which further improves the outcomes. Currently, UPPP, genioglossus and hyoid advancement, and maxillomandibular advancement (MMA) are used widely to improve upper airway obstruction in OSA. Of the available surgical interventions, MMA has been shown to have the highest success rate [9–11]. Several years ago, radiofrequency (RF) energy was investi-

gated as a potential treatment of OSA by ablation of the excessive upper airway tissues [12–15]. Based on the initial animal study and subsequent human clinical trials, RF has been shown to improve OSA [15,16].

Clinical evaluation

Before embarking on any surgical procedure, a thorough head and neck evaluation combined with fiberoptic pharyngolaryngoscopy is performed to isolate and direct treatment at the region or regions of obstruction. A lateral cephalometric radiograph also is used to assist in treatment planning. Although cephalometric radiography is only a static two-dimensional method of evaluating a dynamic three-dimensional area, it does provide useful information on the posterior airway space. The posterior airway space measurement on lateral cephalometric radiography has been shown to correlate with the volume of hypopharyngeal airway on three-dimensional CT scans [17]. It also is a valuable study for assessing the relation of the maxillofacial skeleton and the hyoid bone to the airway. Based on the evaluations, the sites of airway obstruction are identified and a surgical plan is formulated based on the severity of the anatomic obstruction, the severity of sleep apnea, and—more importantly—the patient’s desire and health status.

Oropharyngeal surgery

Uvulopalatopharyngoplasty is an effective surgical procedure to improve airway obstruction in the oropharynx. UPPP consists of the removal of a portion of the soft palate and uvula and a limited amount of the lateral pharyngeal wall and tonsillar

* 750 Welch Road, Suite 317, Palo Alto, CA 94304.
E-mail address: kaseyli@hotmail.com

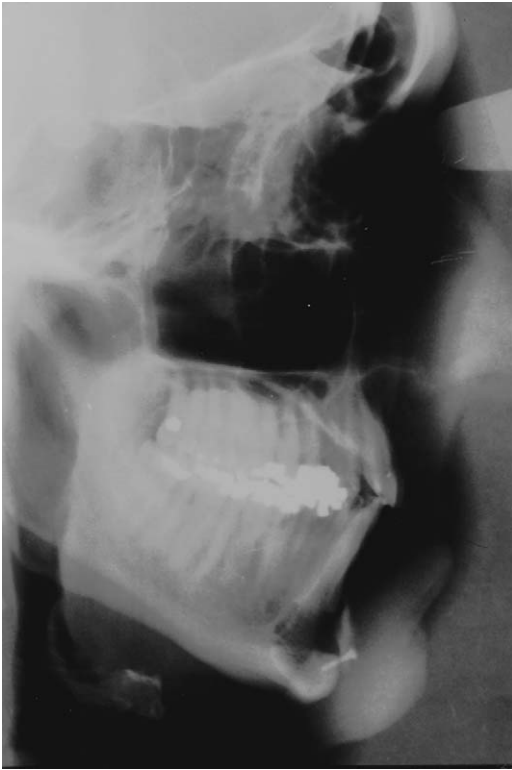

Fig. 1. Lateral cephalometric radiograph before maxillo-mandibular advancement.

tissues (if present). The most crucial aspect of the operation lies not in the amount of the tissue removal but rather in the way the wound is sutured to widen the airway aperture. The temptation to remove an excessive amount of the tissues should be resisted because the risk of complications dramatically increases. At the authors' center, the uvulopalatal flap [18] is the preferred procedure as opposed to the conventional UPPP. The uvulopalatal flap achieves similar result as UPPP but removes less tissue, which potentially reduces the risk of complications. In general, the success rate of UPPP as the sole treatment of OSA is only approximately 40% [19] because many patients have hypopharyngeal and oropharyngeal obstruction. Improvement of the oropharyngeal airway alone is thus insufficient.

Hypopharyngeal surgery

The hypopharyngeal airway is intimately related to the mandible, tongue, and hyoid complex [20,21]. It has been shown that advancing the genioglossus muscle improves the tension of the genioglossus

muscle and decreases its collapsibility during sleep, which alleviates airway obstruction. Obstruction at the hypopharyngeal level can be improved further by anterior movement of the hyoid bone, and numerous reports have supported the concept that surgical intervention at the hyoid level improves the hypopharyngeal airway [22,23].

Initially, advancement of the genioglossus muscle and the hyoid bone was performed simultaneously to improve the hypopharyngeal airway [4]. The technique has evolved over the years to improve outcome and minimize morbidity. The current technique of advancement of genioglossus muscle involves a limited osteotomy intraorally to isolate and advance the genial tubercle [24]. We have not performed both operations simultaneously on a routine basis, however, because most patients with OSA have diffused airway obstruction, and genioglossus muscle advancement is generally combined with UPPP. The added insult to the infrahyoid region by combining the genioglossus muscle and hyoid bone advancement results in increased edema and was believed to be inappropriate in some patients. The authors also have

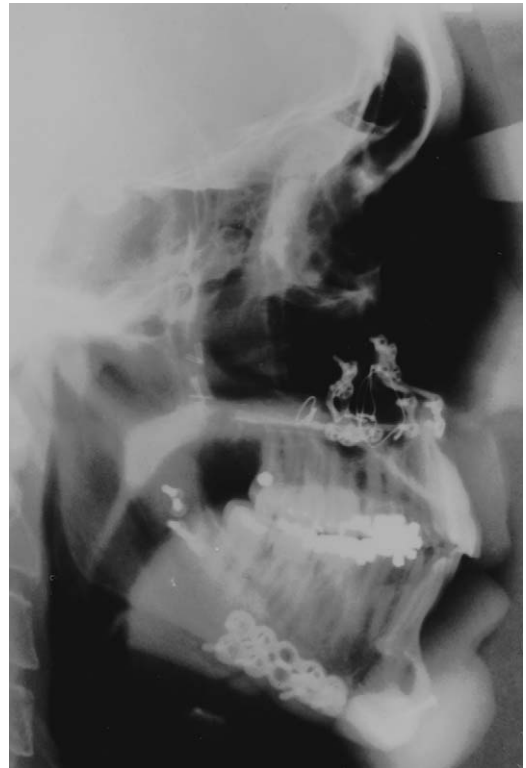

Fig. 2. Lateral cephalometric radiograph after maxillo-mandibular advancement.

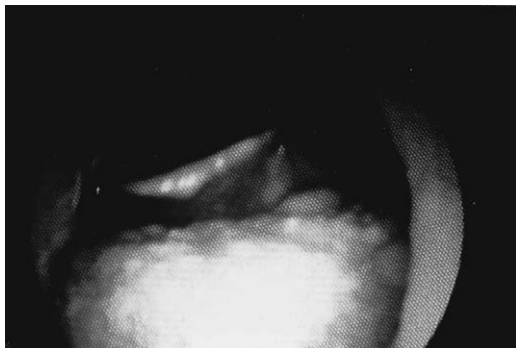

Fig. 3. Fiberoptic laryngoscopy demonstrating tongue base obstruction before maxillomandibular advancement.

found that the hypopharyngeal airway obstruction is resolved with only genioglossus muscle advancement in some patients; thus hyoid bone may not always be necessary. In some elderly patients (> 60 years old), airway edema after simultaneous genioglossus muscle and hyoid bone can result in prolonged dysphagia that may require days to recover. For these reasons the authors perform hyoid bone advancement only in some patients as a separate surgical step.

Maxillomandibular advancement has been shown to be the most effective surgical option in the treatment of OSA [9–11]. MMA achieves enlargement of the pharyngeal and hypopharyngeal airway by physically expanding the skeletal framework. The forward movement of the maxillomandibular complex also improves the tension and collapsibility of the suprahyoid and velopharyngeal musculature. When MMA is performed in patients with persistent OSA after UPPP with genioglossus muscle and hyoid bone advancement, MMA creates further tension and phys-

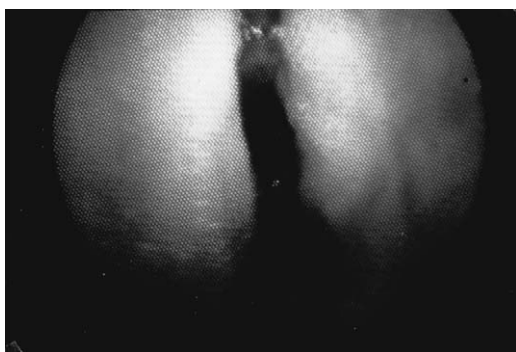


Fig. 4. Fiberoptic laryngoscopy demonstrating significant lateral wall collapse during Mueller's maneuver before maxillomandibular advancement.

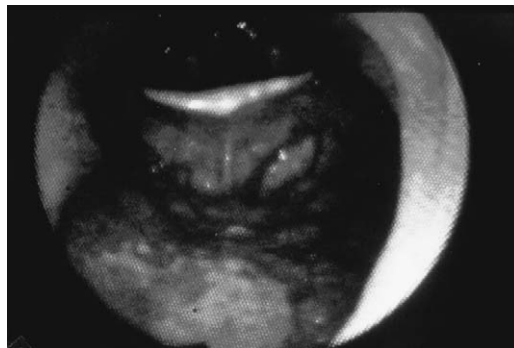


Fig. 5. Fiberoptic laryngoscopy demonstrating improved tongue base obstruction after maxillomandibular advancement.

ical room in the upper airway, which relieves residual obstructions. To maximize airway expansion, a major advancement of the maxillomandibular complex is required to facilitate a successful result (Figs. 1–6). It is important, however, to achieve maximal advancement while maintaining a stable dental occlusion and a balanced esthetic appearance. Over the past 17 years, patients with and without “disproportionate” craniomaxillofacial features have undergone MMA for persistent severe OSA caused by incomplete response to other procedures. Although patients with craniomaxillofacial abnormality, such as maxillary or mandibular deficiencies, usually have improved facial esthetics after surgery, the authors found that many patients with normal cephalometric measurements preoperatively also have an improved facial appearance after MMA, because many patients are middle-age adults who are already showing signs of facial aging caused by soft tissue sagging. Skeletal

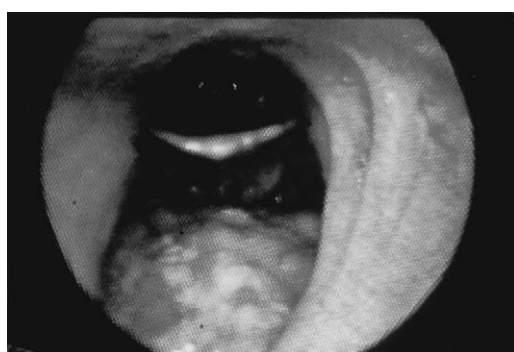


Fig. 6. Fiberoptic laryngoscopy demonstrating improved lateral wall collapse during Mueller's maneuver after maxillomandibular advancement.

expansion of the maxilla and mandible enhances appearance by improving soft tissue support.

Radiofrequency tissue reduction

Using temperature-controlled RF to reduce soft tissue volume in the upper airway was first investigated in the animal tongue model [12]. After RF treatment, tissue volume reduction results in a predictable pattern of wound healing, which consists of coagulation necrosis that leads to fibrosis and tissue contraction. The relationship of lesion size to total RF energy delivery and the resultant volume reduction have been shown to be closely correlated, and the application of RF to the human tongue in a serial fashion was demonstrated to be the most effective use of this technology in improving sleep-disordered breathing (SDB) [15]. More importantly, the safety parameters for temperature-controlled RF in the human tongue were established in that speech and swallowing were not affected based on barium swallow, speech evaluation, and subjective questionnaires [15].

Oropharyngeal and hypopharyngeal surgical outcomes

The authors' surgical results were reported in 1992 [9]. Two hundred thirty-nine patients underwent surgery, with most of the patients requiring intervention at the pharyngeal and hypopharyngeal levels. The overall cure rate was 61% (145/239 patients). The surgical results were comparable to nasal CPAP results. The mean preoperative respiratory disturbance index (RDI) was 48.3, with the postoperative mean RDI of 9.5 (nasal CPAP RDI 7.2, $P = \text{NS}$). The lowest oxygenation saturation (LSAT) improved from 75% to 86.6% (nasal CPAP LSAT 86.4%, $P = \text{NS}$). There was a higher cure rate with mild to moderately

severe disease (approximately 70%) as compared with severe disease (42%). Most of the nonresponders had severe OSA (mean RDI 61.9) and morbid obesity (mean body mass index [BMI] 32.3 kg/m²).

The postoperative morbidity rate was low. The mean hospital stay was 2.1 days. The complications associated with genioglossus muscle and hyoid bone advancement were infection (<2%), injury of tooth roots that required root canal therapy (<1%), permanent paresthesia and anesthesia of the mandibular incisors (<6%), and seroma (<2%). Major complications, such as mandibular fracture, alteration of speech, alteration of swallow, or aspiration, were not encountered.

More than 350 patients underwent MMA with a success rate of approximately 90%. An analysis of 175 patients who underwent MMA between 1988 and 1995 demonstrated that 166 patients had a successful outcome, with a cure rate of 95%. The mean preoperative RDI was 72.3. The mean postoperative RDI was 7.2. The surgical results were comparable to nasal CPAP results (nasal CPAP RDI 8.2, $P = \text{NS}$). The mean LSAT improved from 64% to 86.7% (nasal CPAP LSAT 87.5%, $P = \text{NS}$). 86 patients who failed UPPP and genioglossus muscle/hyoid bone advancement underwent MMA. The mean age of patients was 43.5 years. The cure rate in this group was 97% (83/86 patients). The mean hospital stay for MMA was 2.4 days. The surgical morbidity included transient anesthesia of the lower lip, chin, and cheek in all of the patients. There was an 87% resolution rate between 6 and 12 months. There was no postoperative bleeding or infection. Mild malocclusion encountered in some patients was treated satisfactorily with dental occlusal adjustment. No major skeletal relapse occurred.

To date, 59 patients (49 men) have had long-term follow-up results [25]. The mean age was 47.1 years. The mean BMI was 31.1 kg/m². 19 patients had only subjective (quality of life) results. These patients refused long-term polysomnography for various reasons.

Table 1
Polysomnography results

Parameter	Baseline	Posttreatment	Follow-up	<i>P</i> value ^a
RDI	39.5 ± 32.7	17.8 ± 15.6	28.7 ± 29.4	0.29
Apnea index	22.1 ± 33	4.1 ± 6.2	5.4 ± 10.3	0.88
Hypopnea index	17.4 ± 11.9	13.6 ± 11.5	22.9 ± 23.1	0.20
Total sleep time (min)	337 ± 89	346 ± 75	337 ± 97	0.66
Sleep efficiency index (%)	80 ± 10	80 ± 10	80 ± 10	0.80
Oxygen saturation nadir (%)	81.9 ± 11.6	88.1 ± 5.3	85.8 ± 6.6	0.18
REM sleep (%)	11.4 ± 7.5	17.6 ± 8.9	14.5 ± 7.8	0.16

^a Paired student's *t* tests were performed on the change scores between posttreatment and follow-up.

Table 2
Short Form 36 scores

Domain	Posttreatment	Follow-up	Mean change	<i>P</i> value ^a
Physical functioning	91 ± 13.08	92 ± 15.67	1 ± 20.79	0.44
Role-physical	95 ± 10.54	92.5 ± 23.72	−2.5 ± 27.51	0.61
Bodily pain	87.3 ± 18.37	80.7 ± 19.31	−6.60 ± 27.58	0.77
General health	74.6 ± 16.53	79.1 ± 11.59	4.5 ± 13.01	0.15
Vitality	60 ± 23.57	71 ± 13.5	11 ± 17.76	0.05
Social functioning	81.3 ± 20.58	92.5 ± 16.87	11.2 ± 15.91	0.03
Role emotional	86.6 ± 28.25	96.7 ± 10.44	10.1 ± 31.71	0.17
Mental health	76 ± 13.73	82 ± 7.83	6 ± 15	0.12
Physical component	54 ± 4.08	52.39 ± 7.89	−1.61 ± 9.5	0.69
Mental component	48.99 ± 8.34	54.73 ± 4.06	5.74 ± 8.14	0.03

^a Paired student's *t* tests were performed on the change scores.

ons, including inconvenience, time, and cost. Sixteen of the 19 patients continued to report subjective success with minimal to no snoring, no observed apnea, and no recurrence of excessive daytime sleepiness. All patients reported stable (unchanged) weight to mild weight gain (<5 kg). Three patients reported recurrence of snoring and excessive daytime sleepiness. Long-term polysomnography data were available in 40 patients (33 men). The mean age was 45.6 years. The mean BMI was 31.4 kg/m². The preoperative RDI and LSAT were 71.2 and 67.5, respectively. The 6-month postoperative RDI was 9.3, and the LSAT was 85.6. The mean follow-up period was 50.7 months, and long-term RDI and LSAT were 7.6 and 86.3, respectively. The mean weight at the long-term follow-up was 32.2 kg/m² (*P* = 0.002). 4 patients had recurrent OSA. The 6-month postoperative RDI in these 4 patients was 10.5, but the long-term RDI (61 ± 24.7 months) was 43. The LSAT decreased from 87.5% to 81.8%.

Radiofrequency treatment outcomes

The initial RF tongue base reduction study consisted of 18 patients (17 men). All had the diagnosis of SDB and reported symptoms of daytime sleepiness. The mean age was 44.9 ± 8.7 years. The mean pretreatment BMI was 30.2 ± 5.5 kg/m², and the

mean posttreatment BMI was unchanged at 30.2 ± 5.8 kg/m² [15].

All of the patients had serial RF tongue base reduction under local anesthesia to minimize risks. The mean number of treatment sessions was 5.5 per patient. The mean overall total number of joules administered per patient was 8490 ± 2687 J with 1543 J per treatment session. The mean duration from the completion of treatment to the final PSG was 2.6 ± 0.7 months. The mean RDI improved from 39.5 ± 32.7 to 17.8 ± 15.6 (*P* = 0.003). The mean apnea index improved from 22.1 ± 33.0 to 4.1 ± 6.2 (*P* = 0.023), and the mean hypopnea index improved from 17.4 ± 11.9 to 13.6 ± 11.5 (*P* = 0.326). The mean LSAT improved from 81.9 ± 11.6 to 88.1 ± 5.3 (*P* = 0.03). The mean Epworth Sleepiness Scale improved from 10.4 ± 5.6 to 4.1 ± 3.2 (*P* = 0.0001), and the speech and swallowing visual analog scale did not change from baseline.

Sixteen of the original 18 patients completed a long-term follow-up study [16]. 2 patients (both men) were lost to follow-up. The mean follow-up period was 28 ± 4 months. There was a mean weight increase of 3.1 ± 7.9 kg. The follow-up PSG data showed a persistent improvement of the mean apnea index; however, there was a trend of worsening hypopnea index, which resulted in a trend of worsening RDI (Table 1). There was also a trend of worsening LSAT.

Table 3
Questionnaire visual analog scale results

Parameter	Baseline	Posttreatment	Follow-up	<i>P</i> value ^a
Epworth Sleepiness Scale	10.4 ± 5.7	4.1 ± 3.2	4.5 ± 3.4	1
Snoring	4.7 ± 3.5	2 ± 1.4	3.5 ± 2.7	0.01
Speech	1.2 ± 1.9	0.6 ± 1.1	2.5 ± 2.9	0.02
Swallowing	1.1 ± 1.9	0.3 ± 0.5	1.3 ± 2.2	0.09

^a Paired student's *t* tests were performed on the change scores between posttreatment and follow-up.

The quality-of-life measurements by Short Form 36 (Table 2) and excessive daytime sleepiness by the Epworth Sleepiness Scale (Table 3) demonstrated persistent improvement compared with baseline, and no differences were found compared with posttreatment results. Although no changes in swallowing or speech were reported, the visual analog scale measurement did increase significantly (see Table 3).

Summary

Nasal CPAP is and should be the first-line treatment for OSA. Any physician who uses nasal CPAP undoubtedly recognizes that this treatment modality has limitations, however. The authors believe that surgery offers a viable alternative to nasal CPAP in patients who are intolerant of nasal CPAP. Potential risks and complications must be explained fully to any potential surgical candidate. The selection of surgical procedure(s) should be determined based on a patient's airway anatomy, medical status, severity of sleep apnea, and his or her desire and preference.

References

- [1] Kuhlo W, Doll E, Frank MD. Erfolgreiche Behandlung eines Pickwick-syndroms durch eine dauertrachealkanüle. *Dtsch Med Wochenschr* 1969;94:1286–90.
- [2] Ikematsu T. Study of snoring. 4th report. *Jpn Otol Rhinol Laryngol Soc* 1964;64:434–5.
- [3] Fijita S, Conway W, Zorick F, Roth T. Surgical correction of anatomic abnormalities of obstructive sleep apnea syndrome: uvulopalatopharyngoplasty. *Otolaryngol Head Neck Surg* 1981;89:923–34.
- [4] Riley RW, Guilleminault C, Powell NB, Derman S. Mandibular osteotomy and hyoid bone advancement for obstructive sleep apnea: a case report. *Sleep* 1984; 7:79–82.
- [5] Riley RW, Powell NB, Guilleminault C. Obstructive sleep apnea and the hyoid: a revised surgical procedure. *Otolaryngol Head Neck Surg* 1994;111:717–21.
- [6] Powell NB, Guilleminault C, Riley RW. Mandibular advancement and obstructive sleep apnea syndrome. *Bull Eur Physiopathol Respir* 1983;19:607–10.
- [7] Bear SE, Priest JH. Sleep apnea syndrome: correction with surgical advancement of the mandible. *J Oral Surg* 1980;38:543–9.
- [8] Kuo PC, West RA, Bloomquist DS, et al. The effect of mandibular osteotomy in three patients with hypersomnia and sleep apnea. *Oral Surg Oral Med Oral Pathol* 1979;48:385–92.
- [9] Riley RW, Powell NB, Guilleminault C. Obstructive sleep apnea syndrome: a review of 306 consecutively treated surgical patients. *Otolaryngol Head Neck Surg* 1993;108:117–25.
- [10] Li KK, Riley RW, Powell NB, Gervacio L, Troell RJ, Guilleminault C. Obstructive sleep apnea surgery: patients' perspective and polysomnographic results. *Otolaryngol Head Neck Surg* 2000;123:572–5.
- [11] Waite PD, Wooten V. Maxillomandibular advancement surgery in 23 patients with obstructive sleep apnea syndrome. *J Oral Maxillofac Surg* 1989;47:1256–61.
- [12] Powell NB, Riley RW, Troell RJ, et al. Radiofrequency volumetric reduction of the tongue. *Chest* 1997;111: 1348–55.
- [13] Powell NB, Riley RW, Troell RJ, et al. Radiofrequency volumetric tissue reduction of the palate in subjects with sleep-disordered breathing. *Chest* 1998;113: 1163–74.
- [14] Li KK, Powell NB, Riley RW, et al. Radiofrequency volumetric reduction for treatment of turbinate hypertrophy: a pilot study. *Otolaryngol Head Neck Surg* 1998;119:569–73.
- [15] Powell NB, Riley RW, Guilleminault C. Radiofrequency tongue base reduction in sleep-disordered breathing. *Otolaryngol Head Neck Surg* 1999;120: 656–64.
- [16] Li KK, Powell NB, Riley RW, Guilleminault C. Temperature-controlled radiofrequency tongue base reduction for sleep-disordered breathing: long-term outcomes. *Laryngoscope* 2002;112:230–4.
- [17] Riley RW, Powell NB. Maxillofacial surgery and obstructive sleep apnea syndrome. *Otolaryngol Clin North Am* 1990;23:809–26.
- [18] Powell N, Riley R, Guilleminault C, et al. A reversible uvulopalatal flap for snoring and sleep apnea syndrome. *Sleep* 1996;19:593–9.
- [19] Sher AE, Schechtman KB, Piccirillo JF. The efficacy of surgical modifications of the upper airway in adults with obstructive sleep apnea syndrome. *Sleep* 1996; 19:156–77.
- [20] Lowe A, Gionhaku N, Tadeuchi K, et al. Three dimensional reconstructions of the tongue and airway in adult subjects with obstructive sleep apnea. *Am J Orthod* 1986;90:364–74.
- [21] Rojewski TE, Schuller DE, Clark RW, et al. Videoendoscopic determination of the mechanism of obstruction in obstructive sleep apnea. *Otolaryngol Head Neck Surg* 1984;92:127–31.
- [22] Van de Graaf WB, Gottfried SB, Mitra J, et al. Respiratory function of hyoid muscles and hyoid arch. *J Appl Physiol* 1984;57:197–204.
- [23] Patton TJ, Thawley SE, Water RC, et al. Expansion hyoid-plasty: a potential surgical procedure designed for selected patients with obstructive sleep apnea syndrome. Experimental canine results. *Laryngoscope* 1983;93:1387–96.
- [24] Li KK, Riley RW, Powell NB, Troell RJ. Obstructive sleep apnea surgery: genioglossus advancement revisited. *J Oral Maxillofac Surg* 2001;59:1181–4.
- [25] Riley RW, Powell NB, Li KK, Troell RJ, Guilleminault C. Surgery and obstructive sleep apnea: long-term clinical outcomes. *Otolaryngol Head Neck Surg* 2000; 122:415–21.